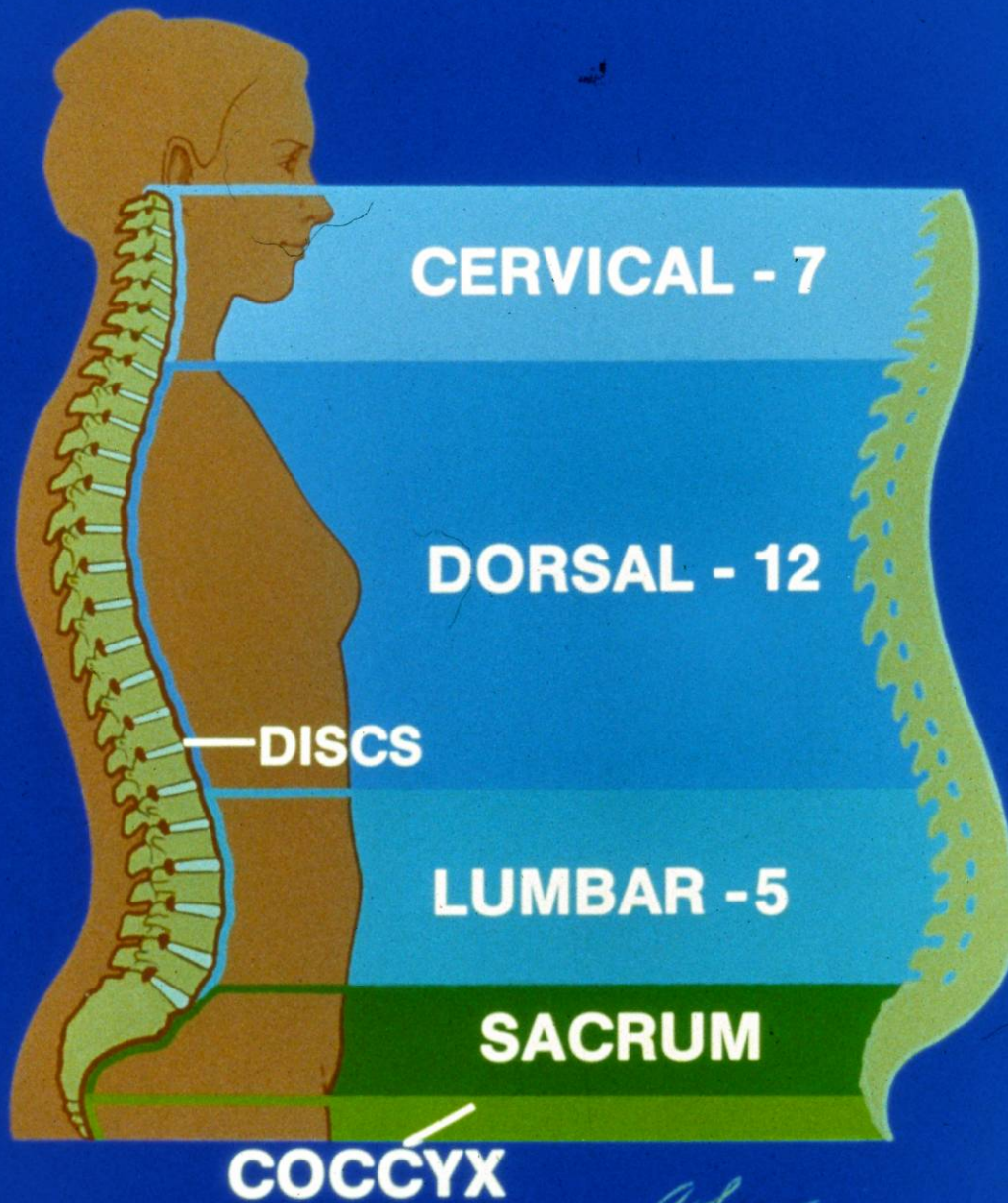


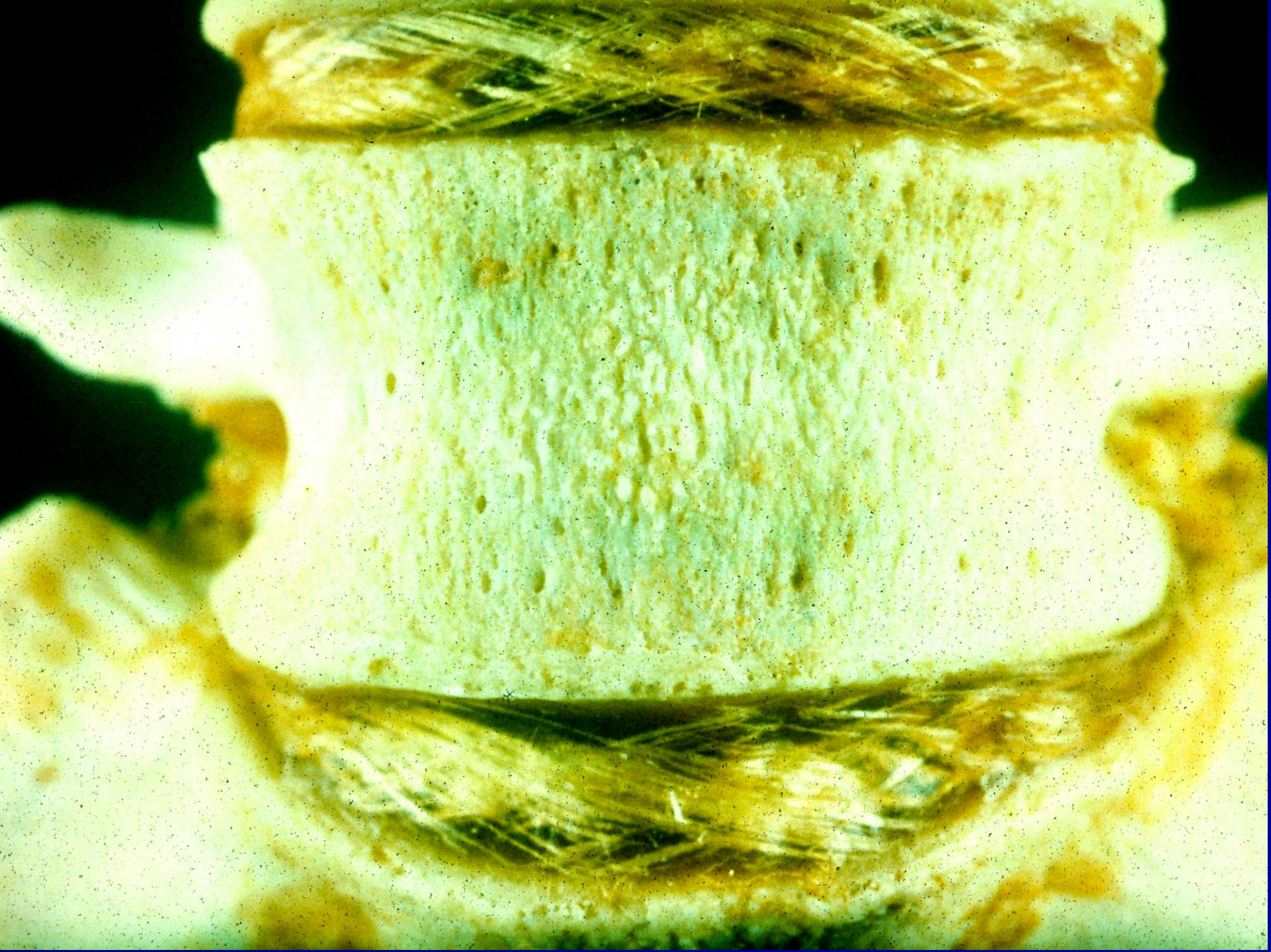# MY AGING BACK

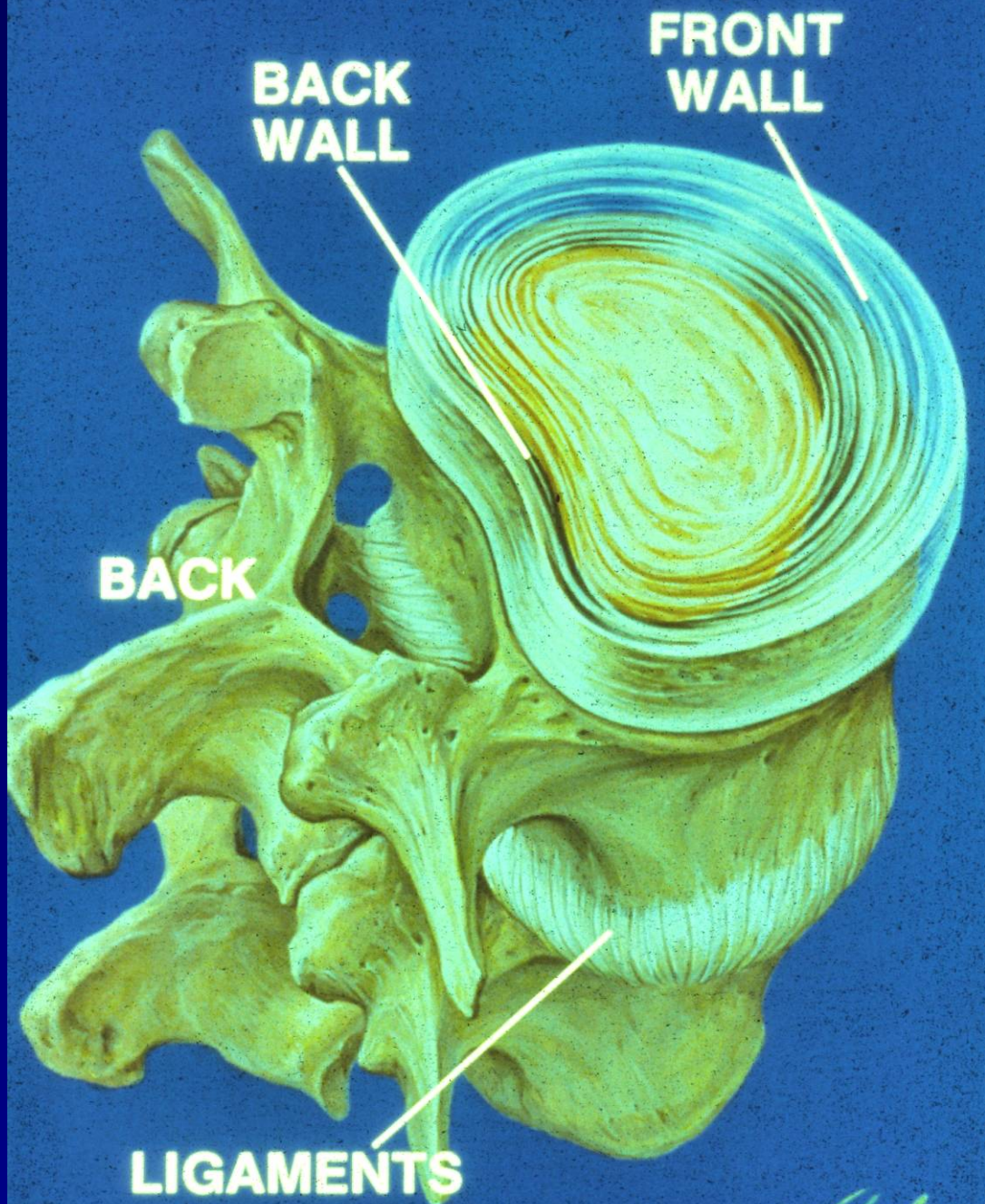
Larry Herron, M.D.



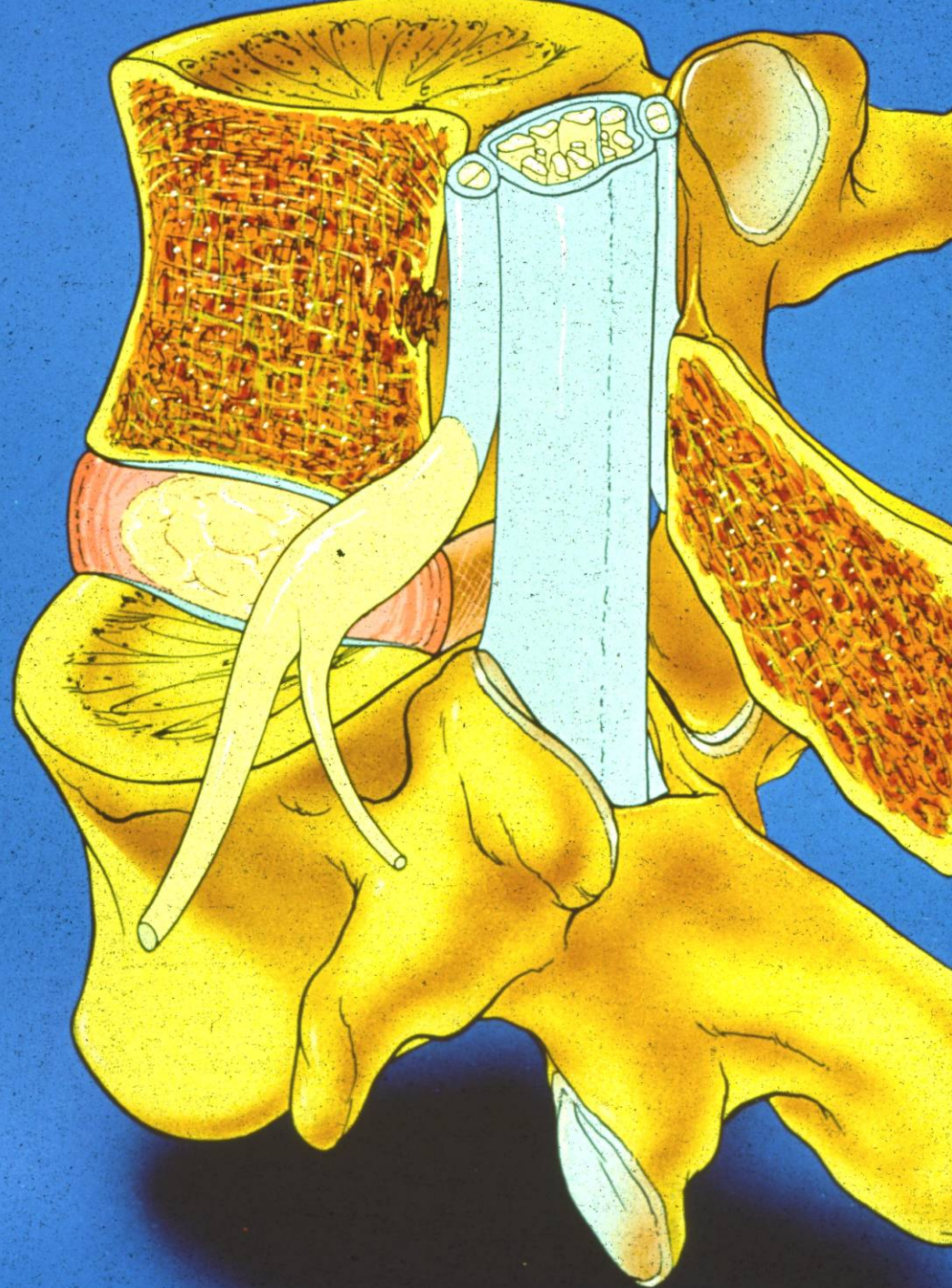
# THE SPINE



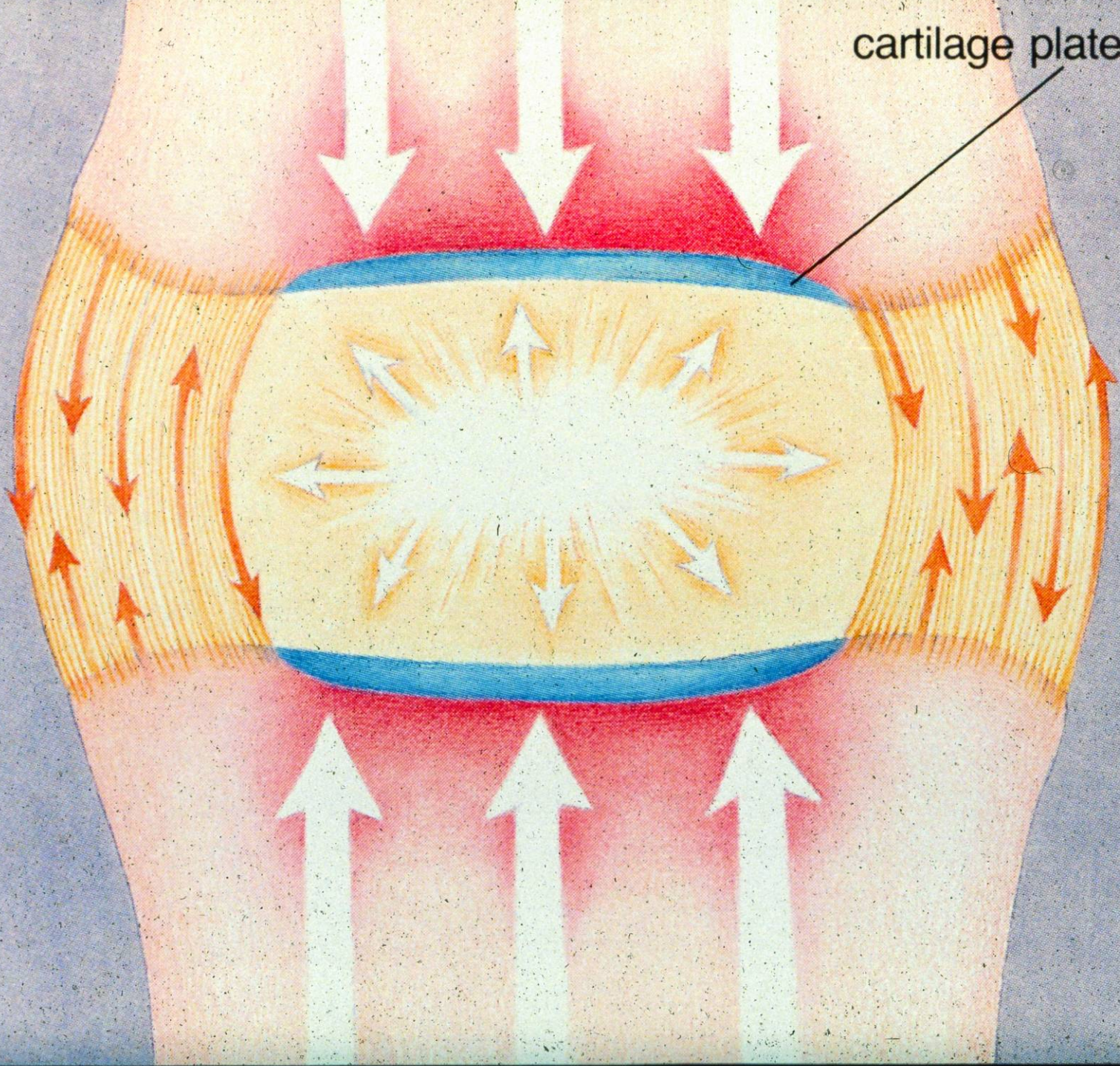


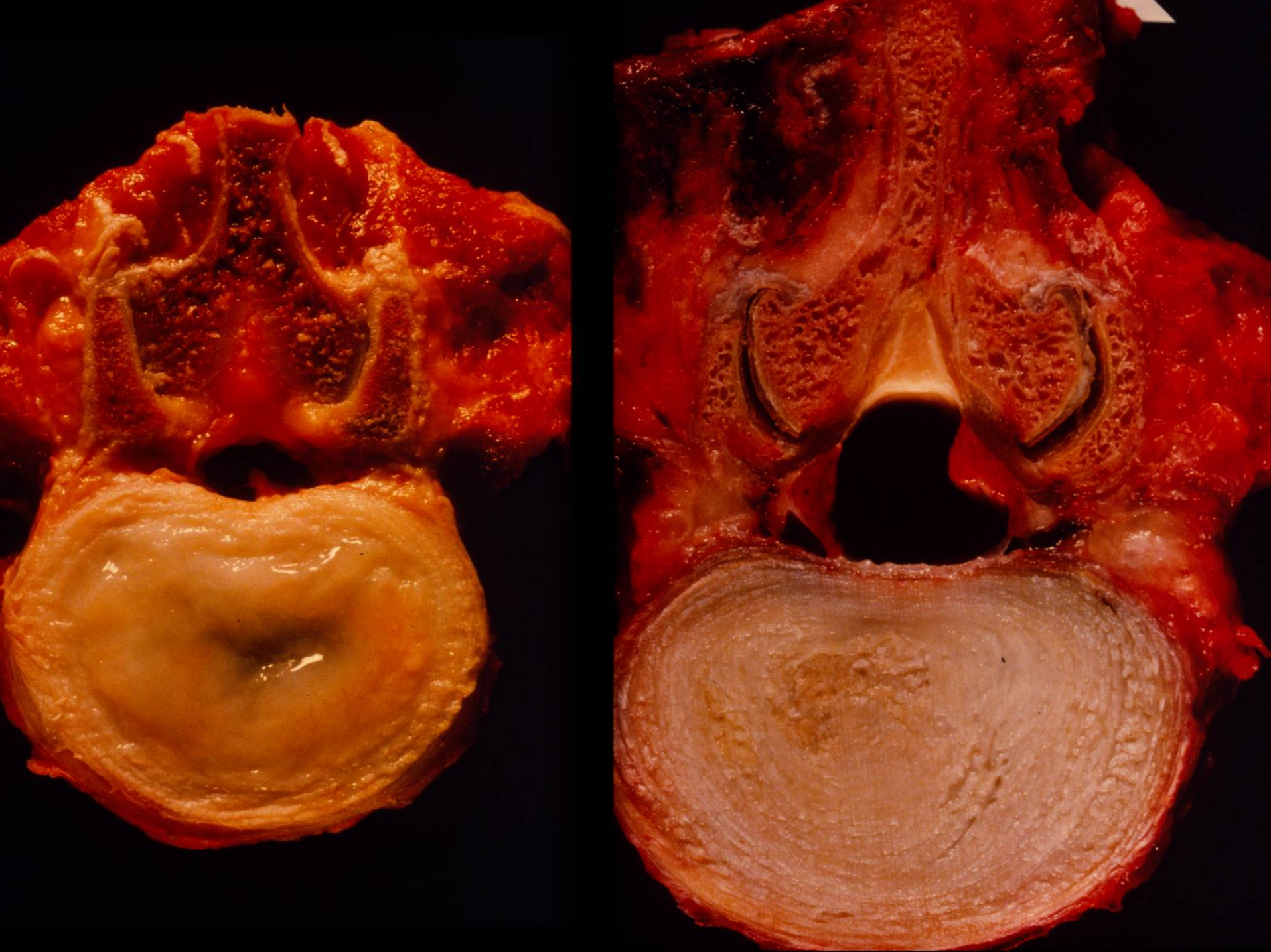


*W. H. R.*



cartilage plate




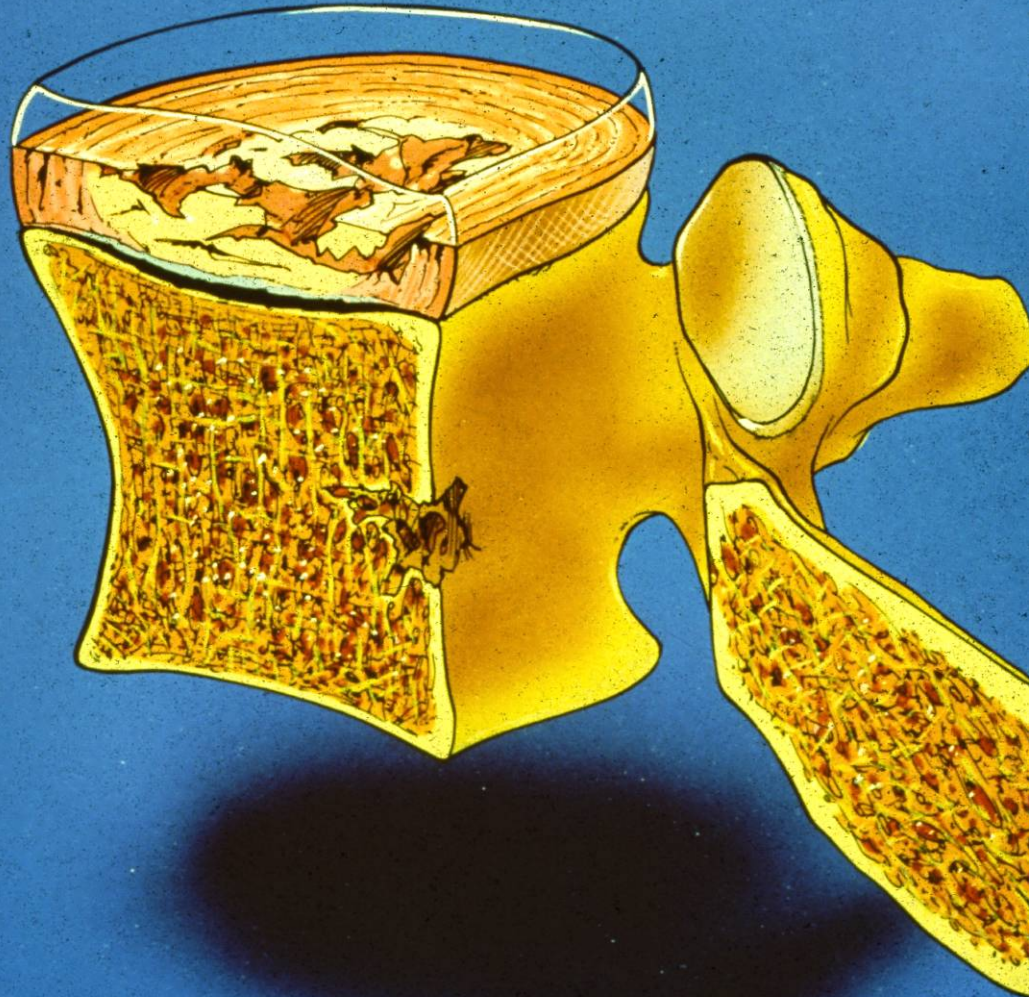


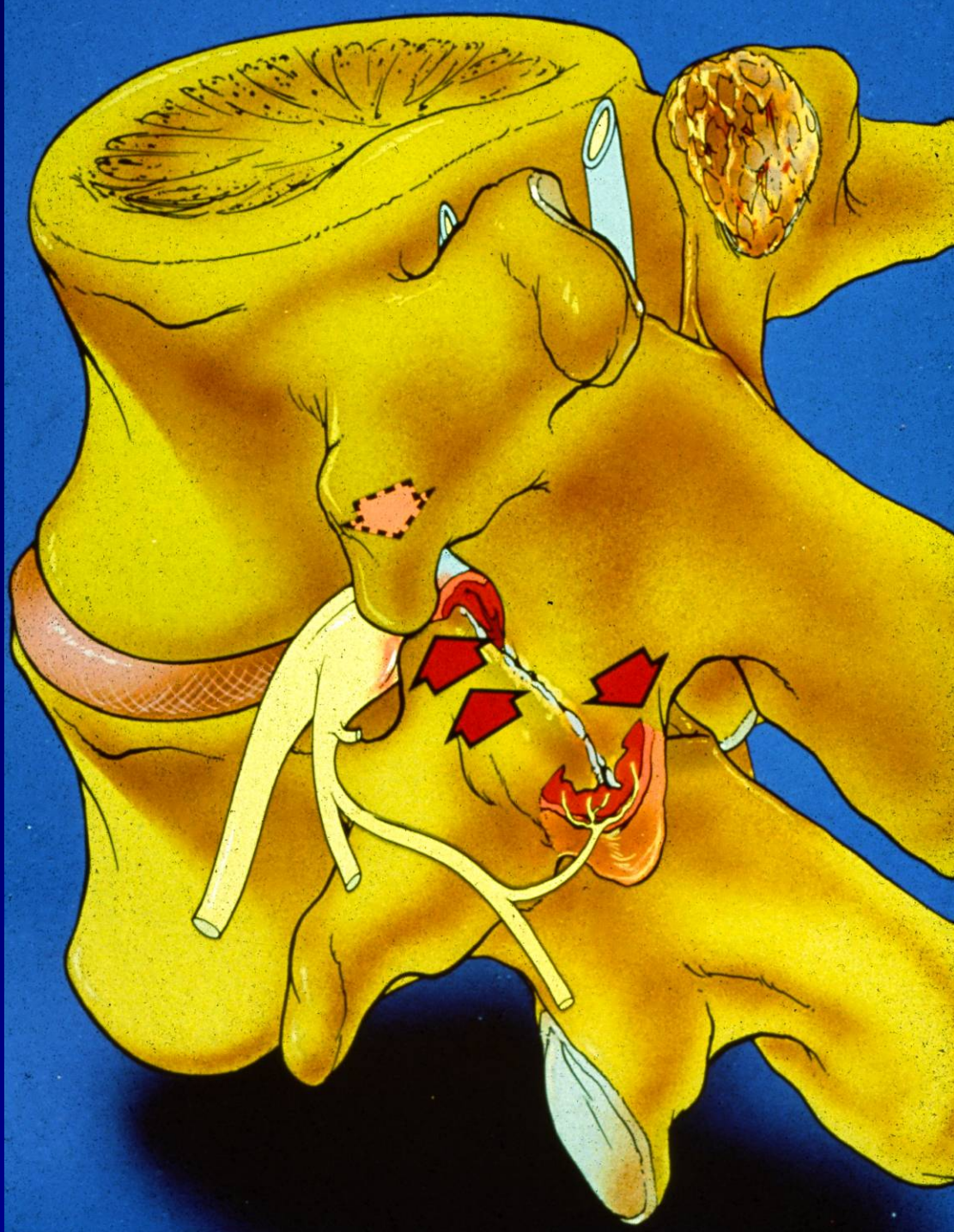


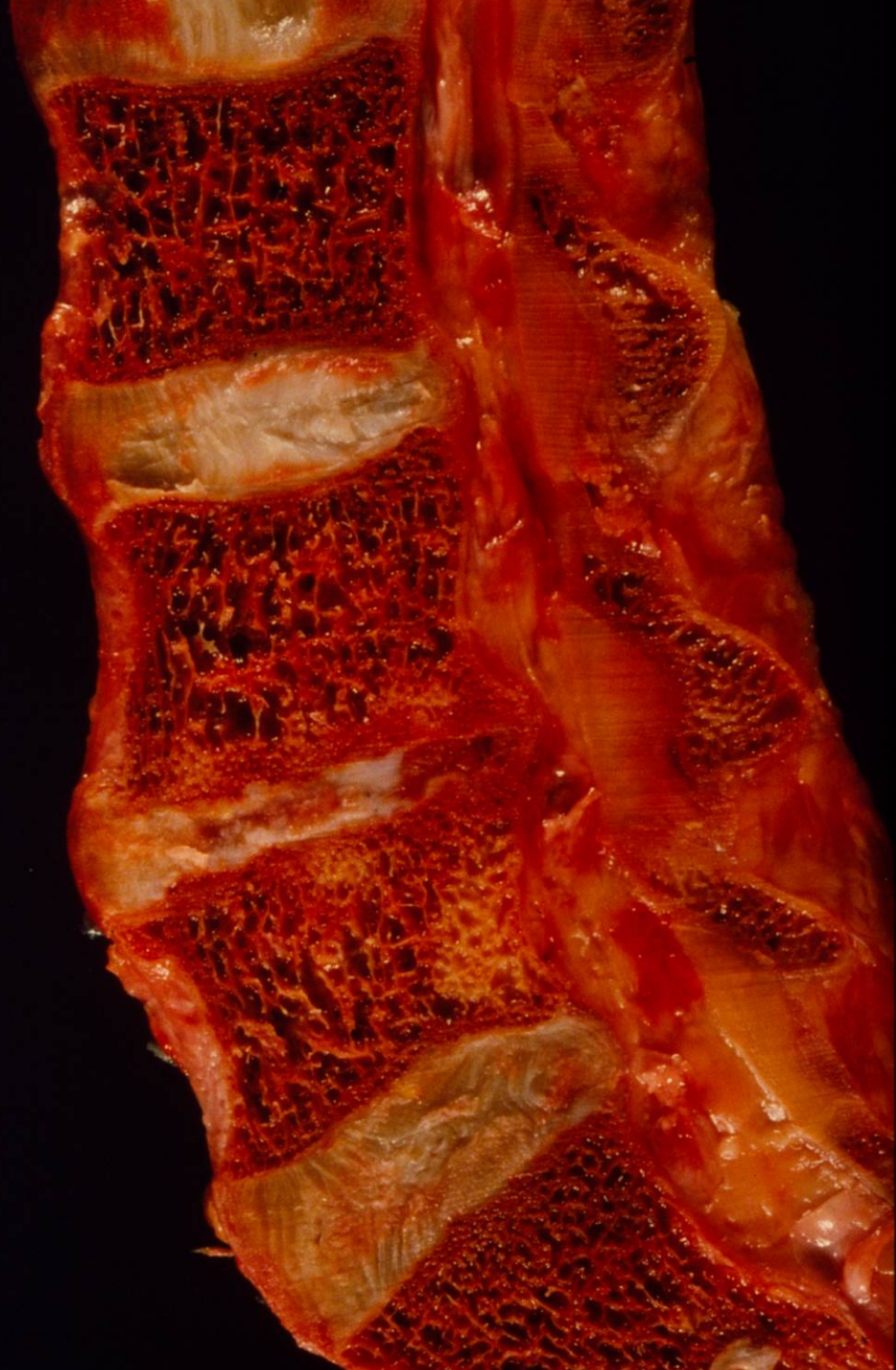
# DISC DEGENERATION

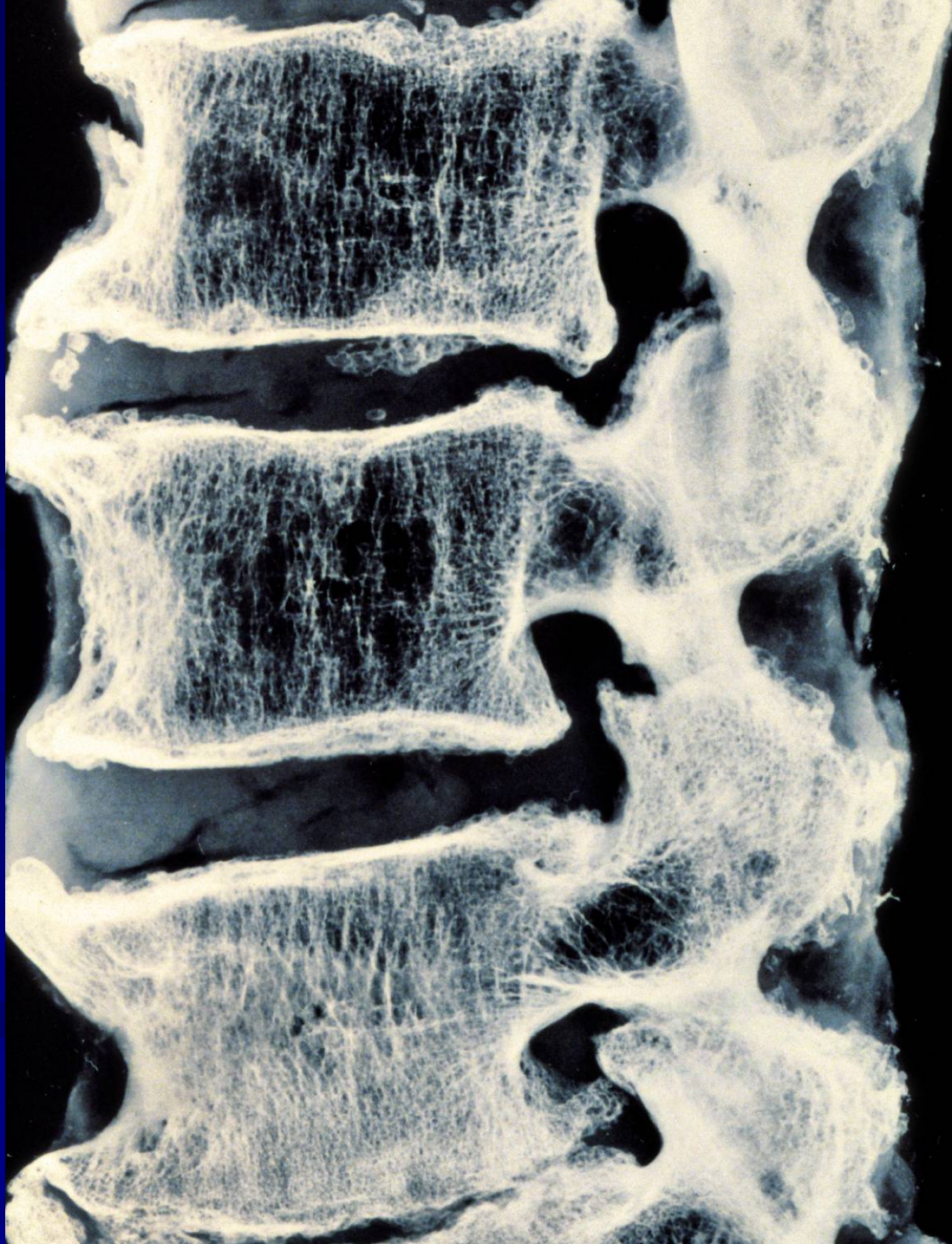MILES ON THE  
SHOCK ABSORBERS

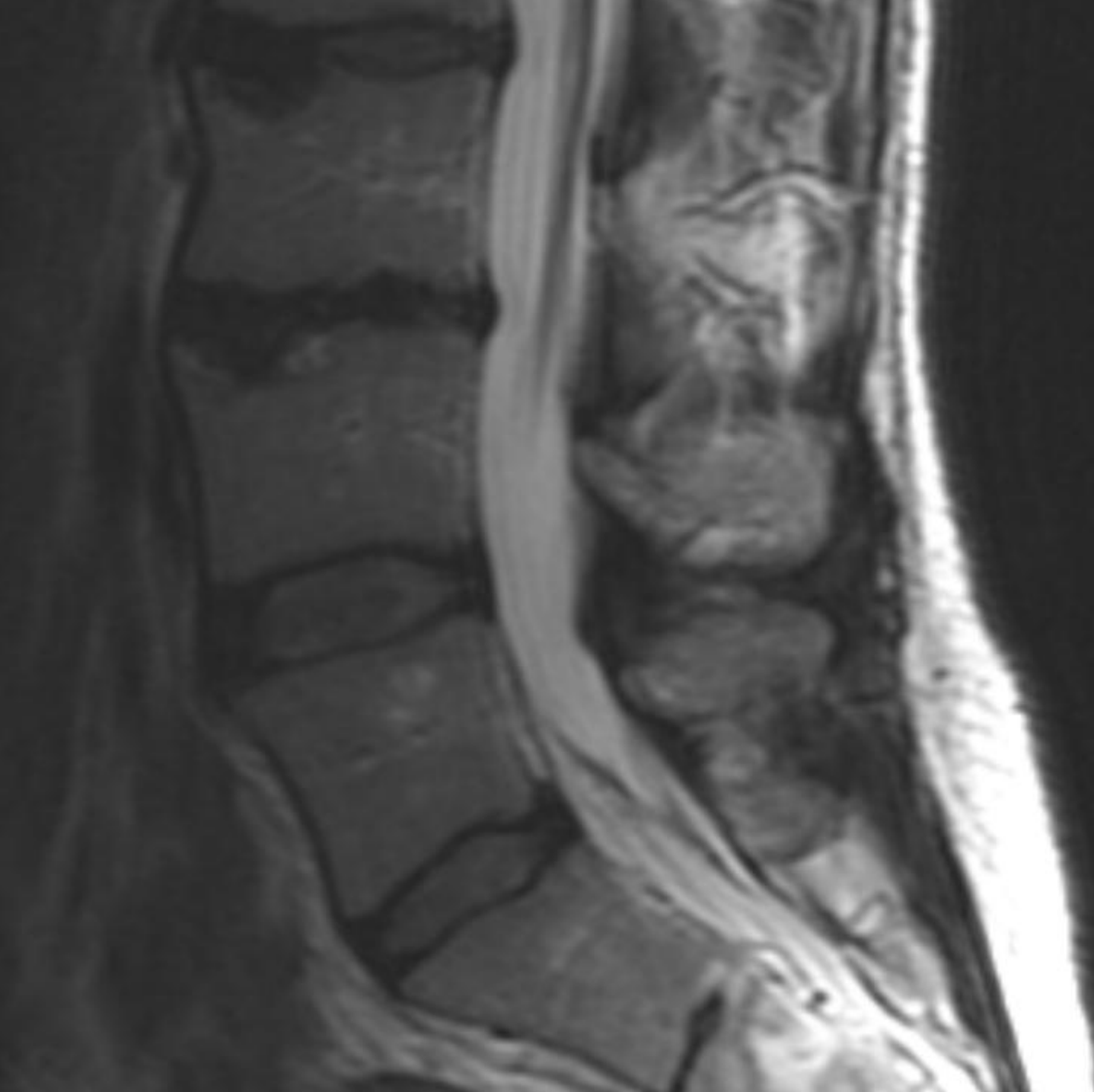










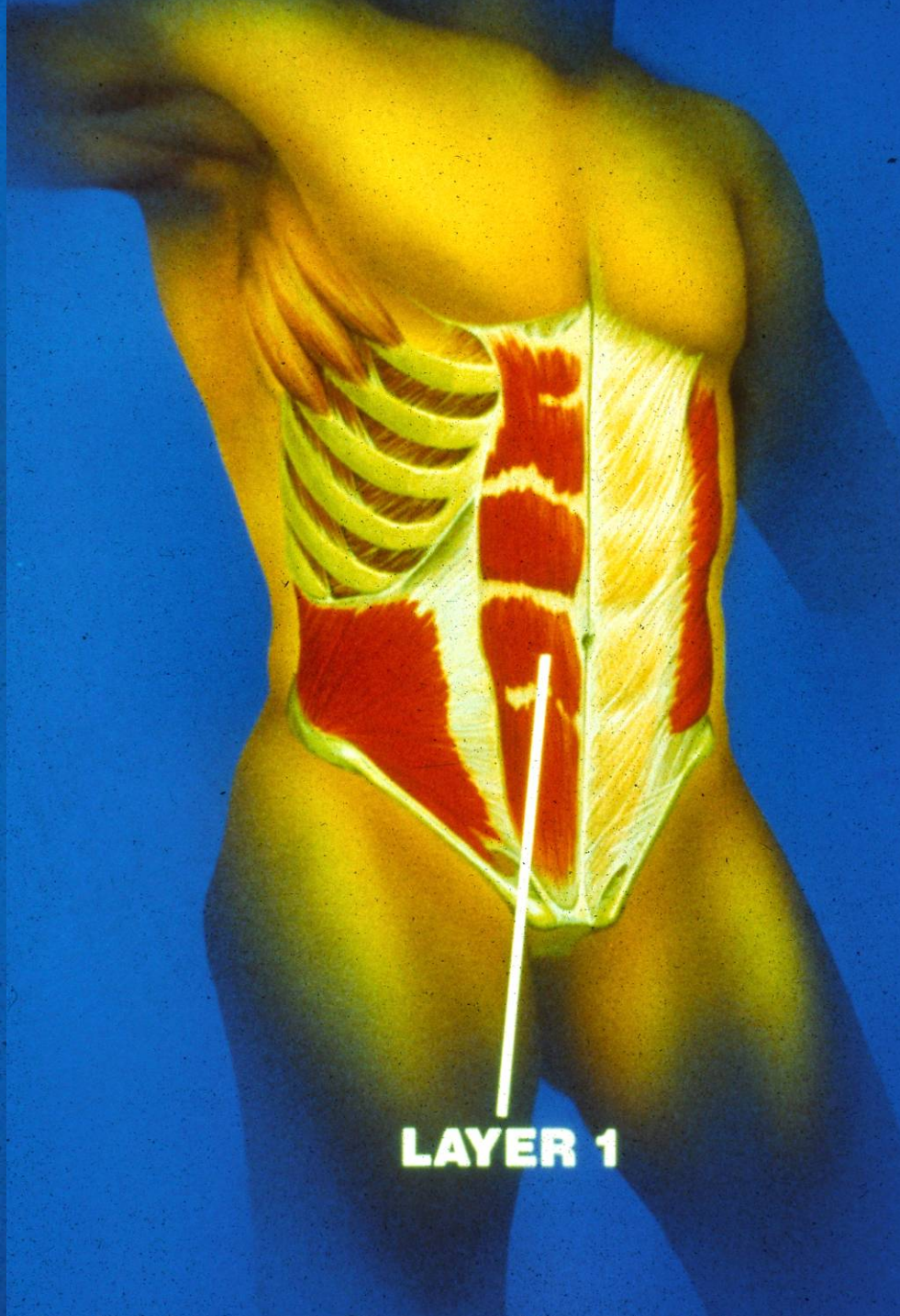
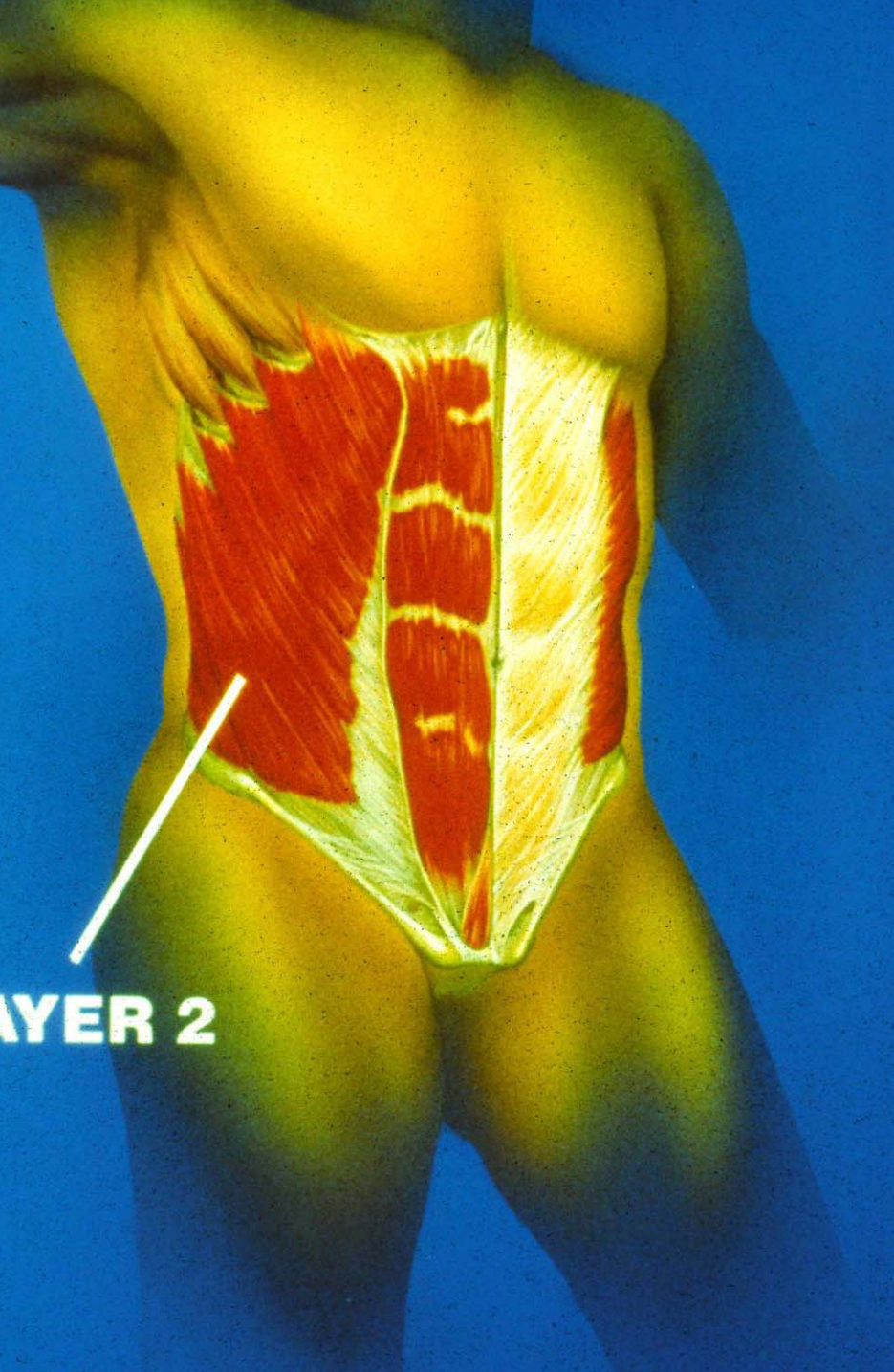

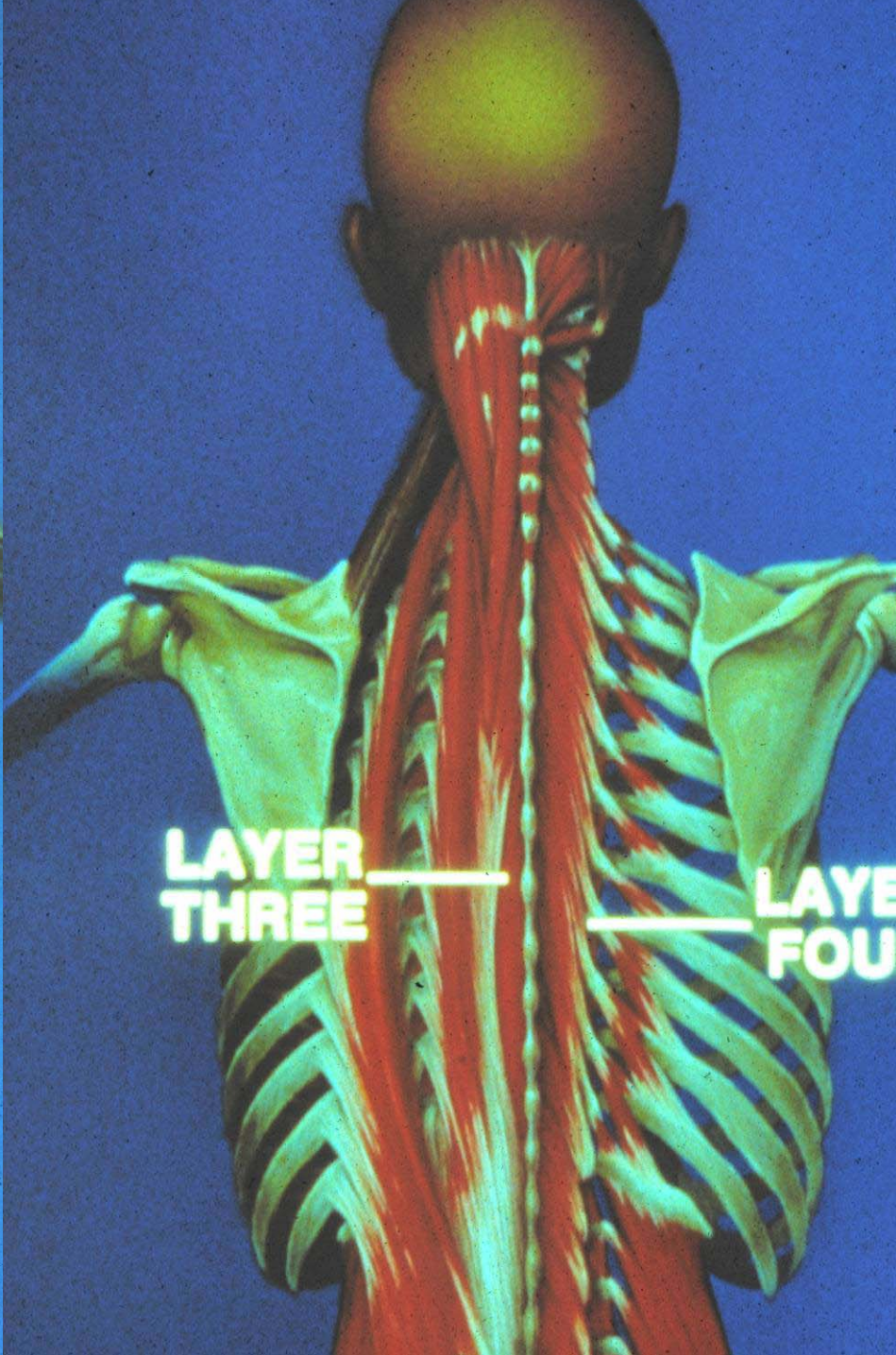
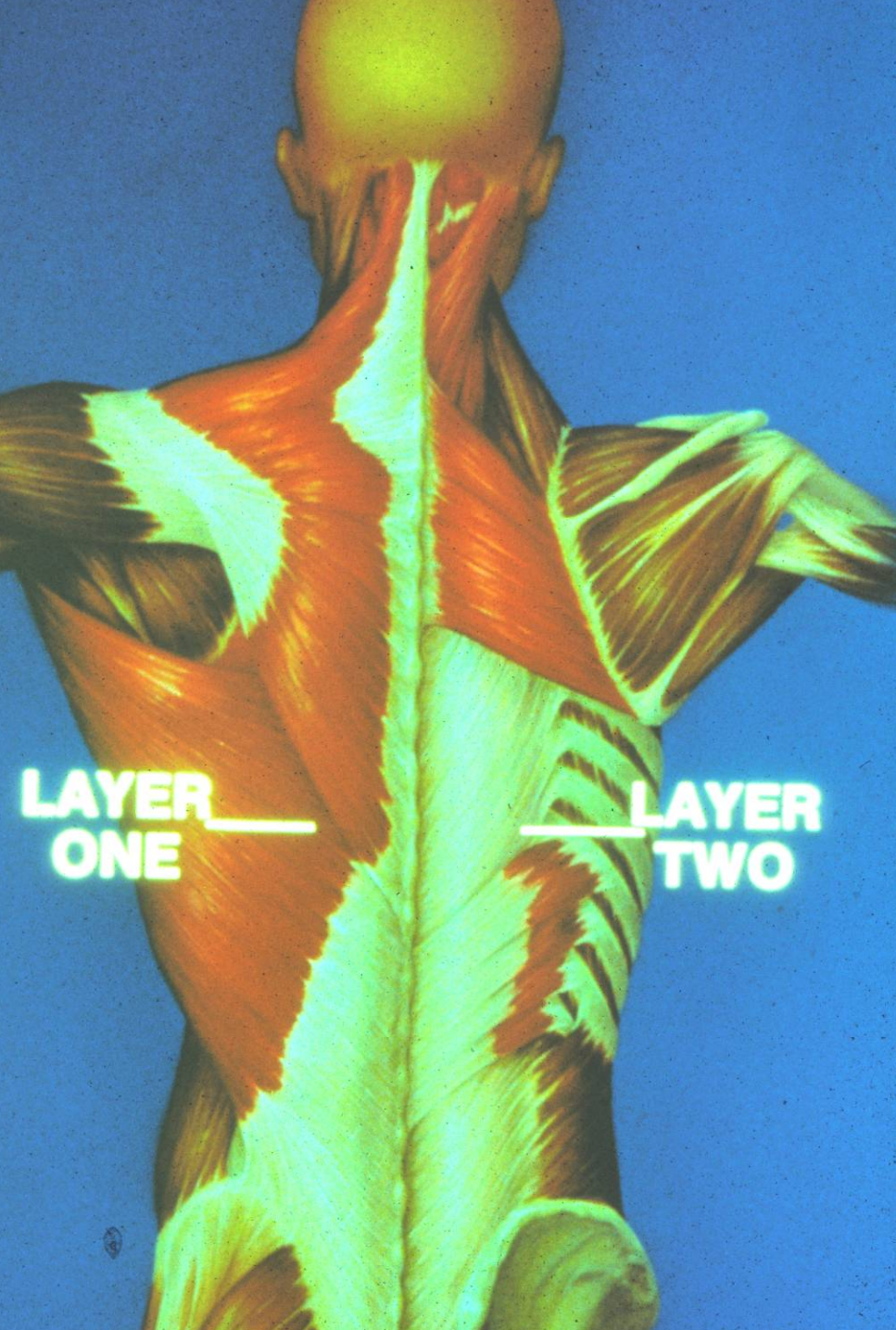


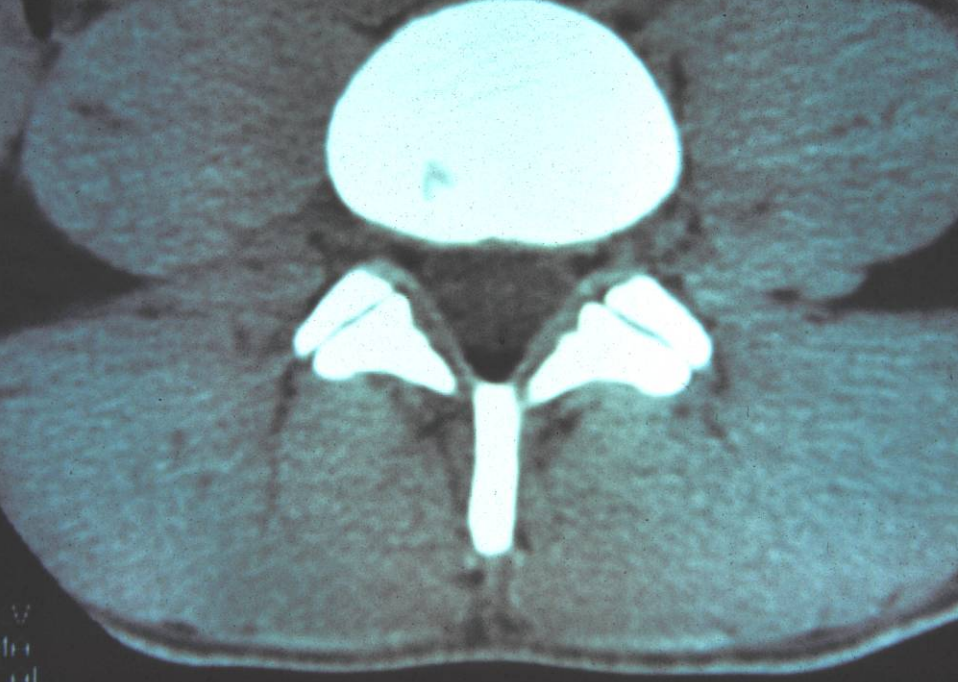




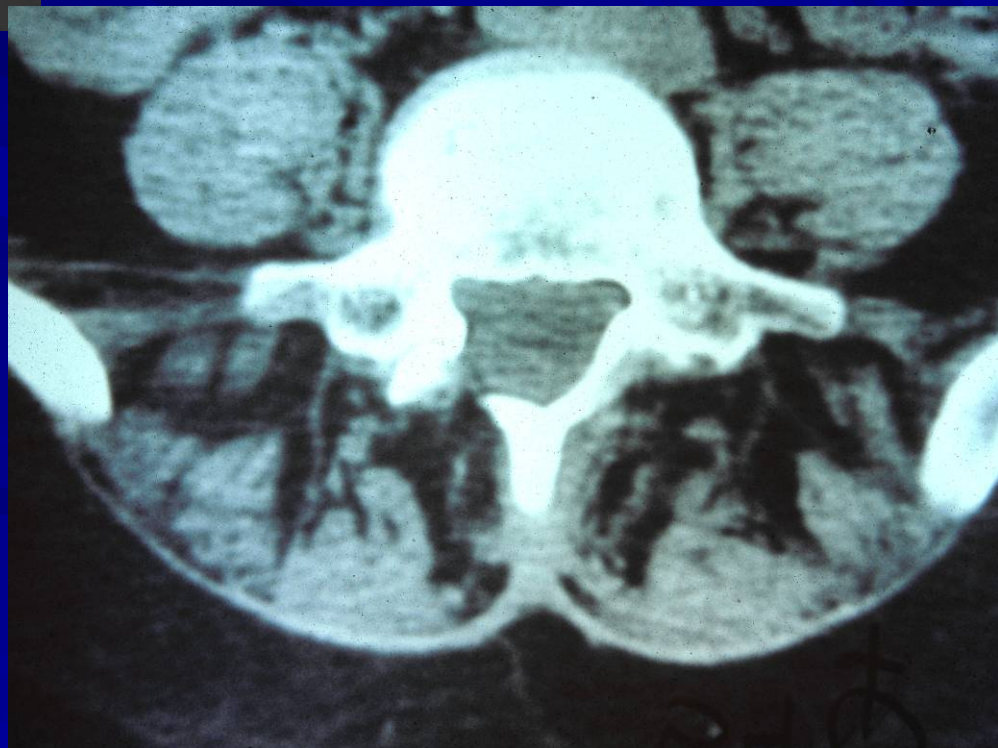









7  
10  
11  
114

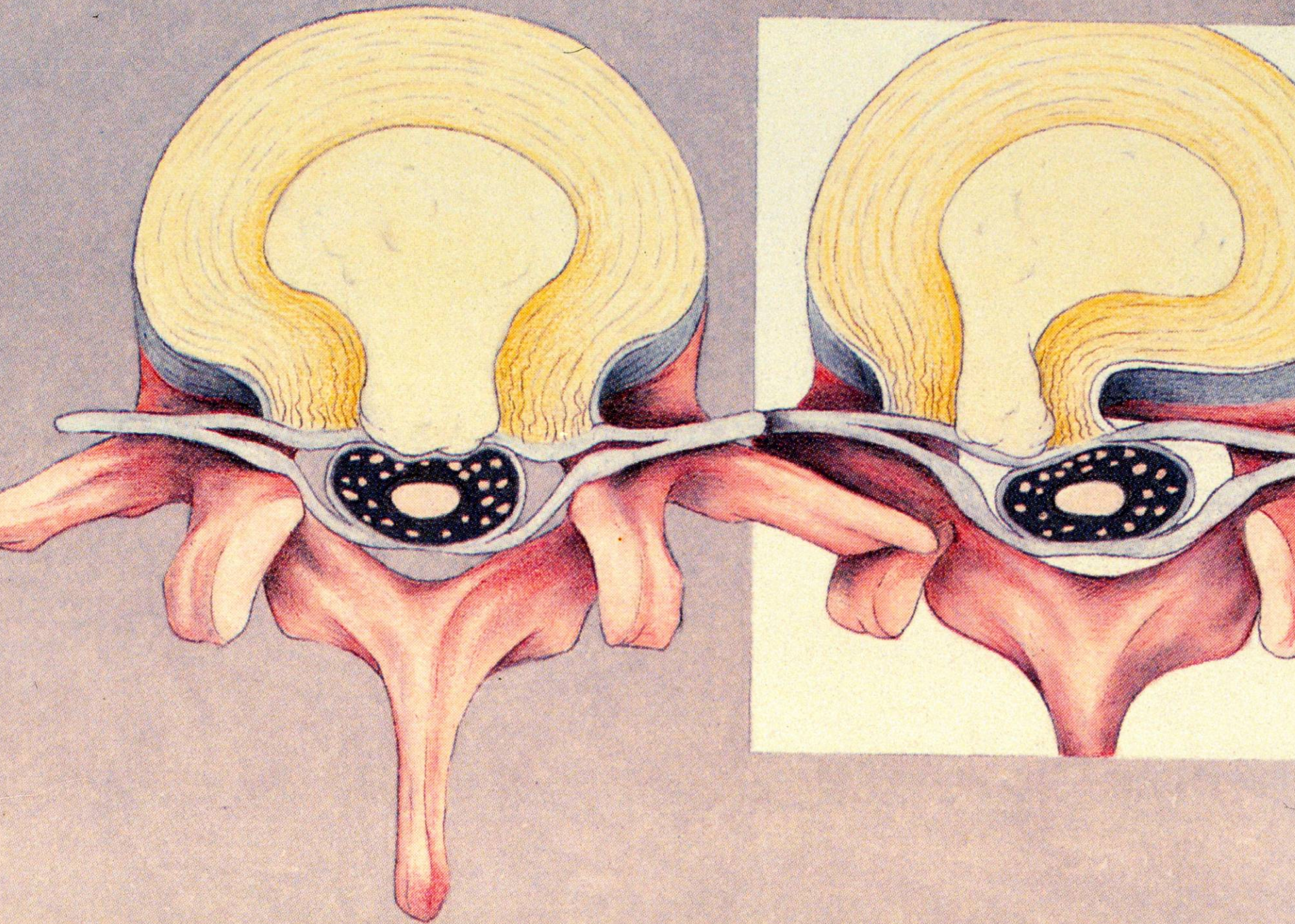


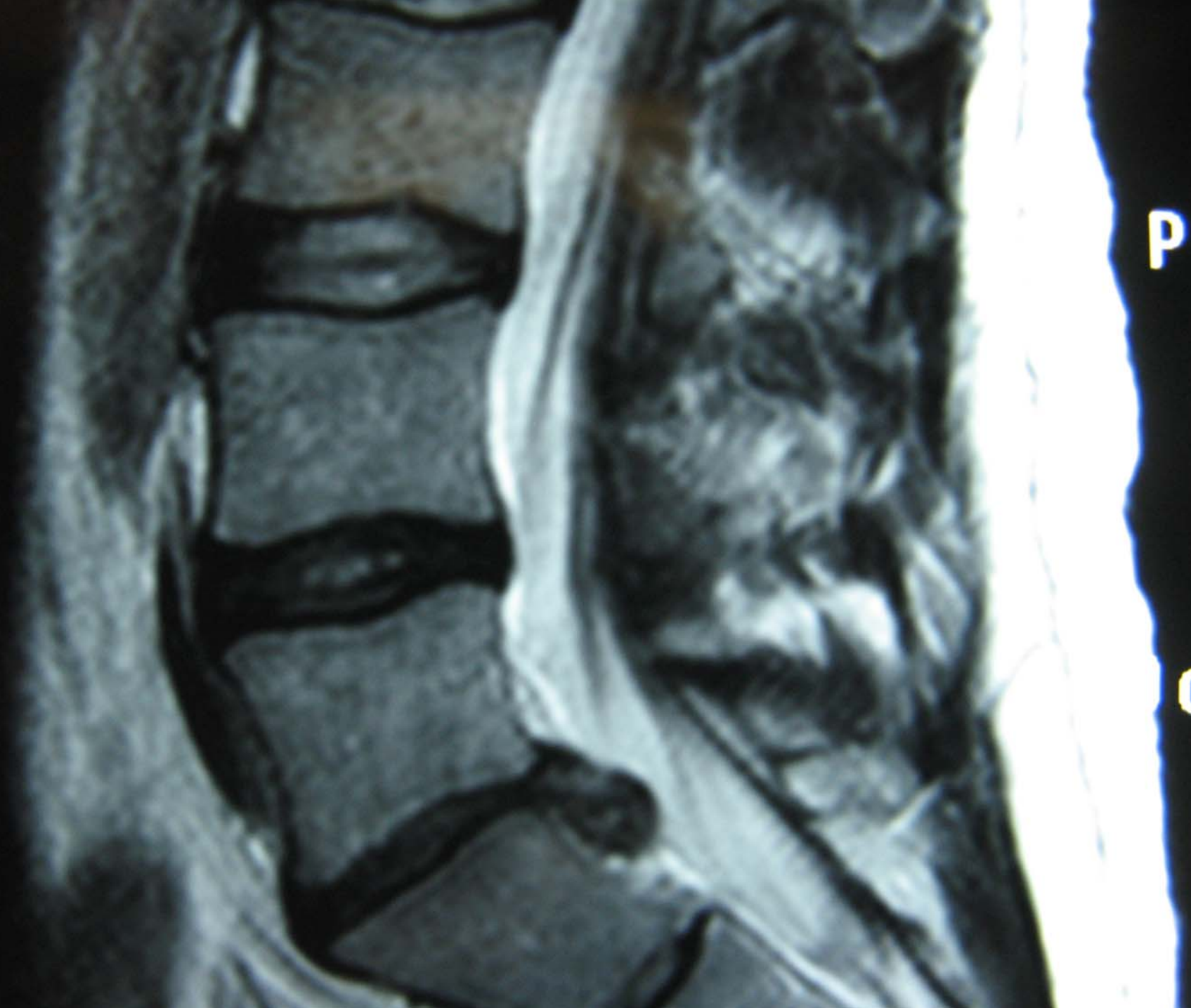




# DISC HERNIATION

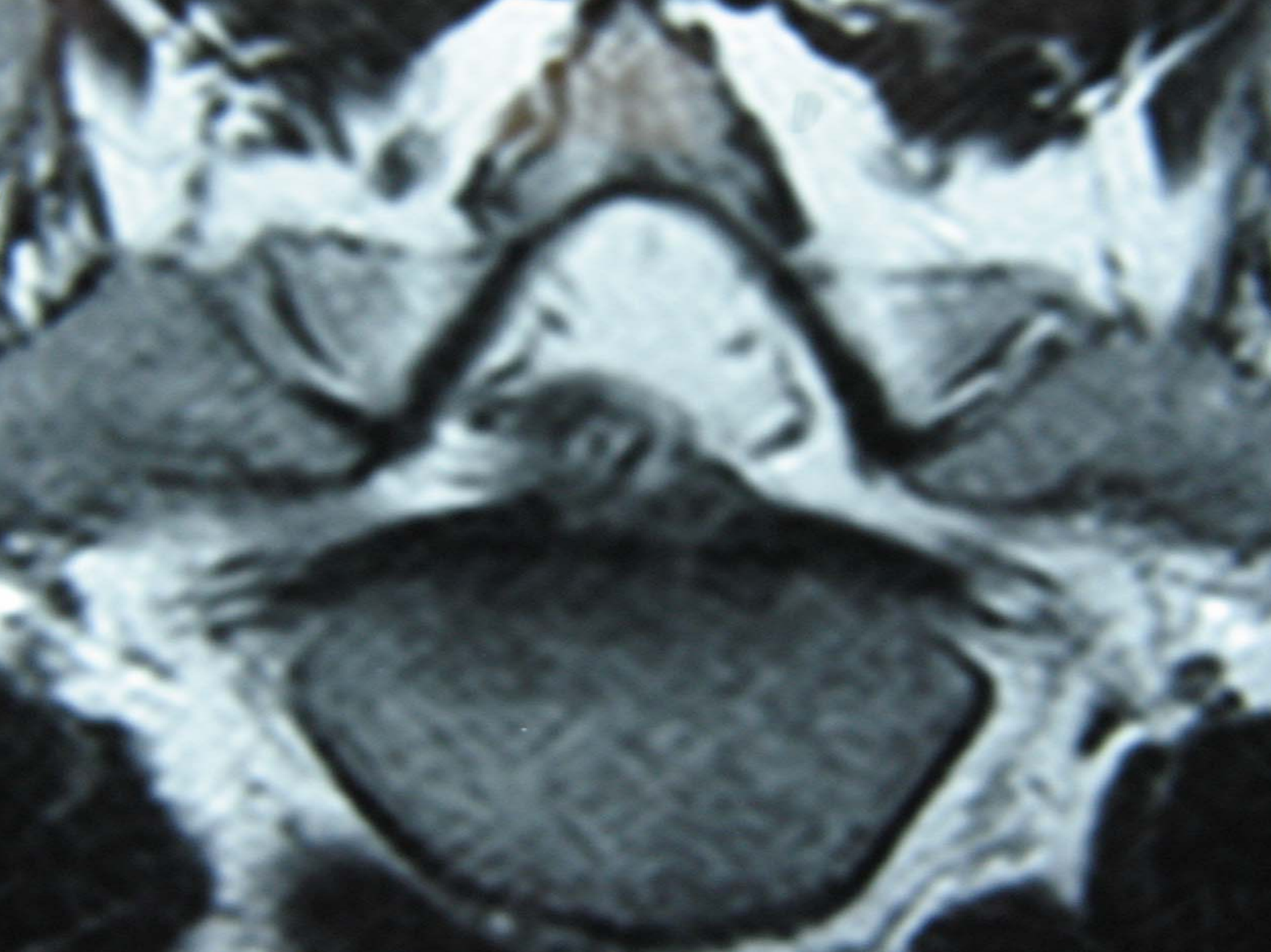






P

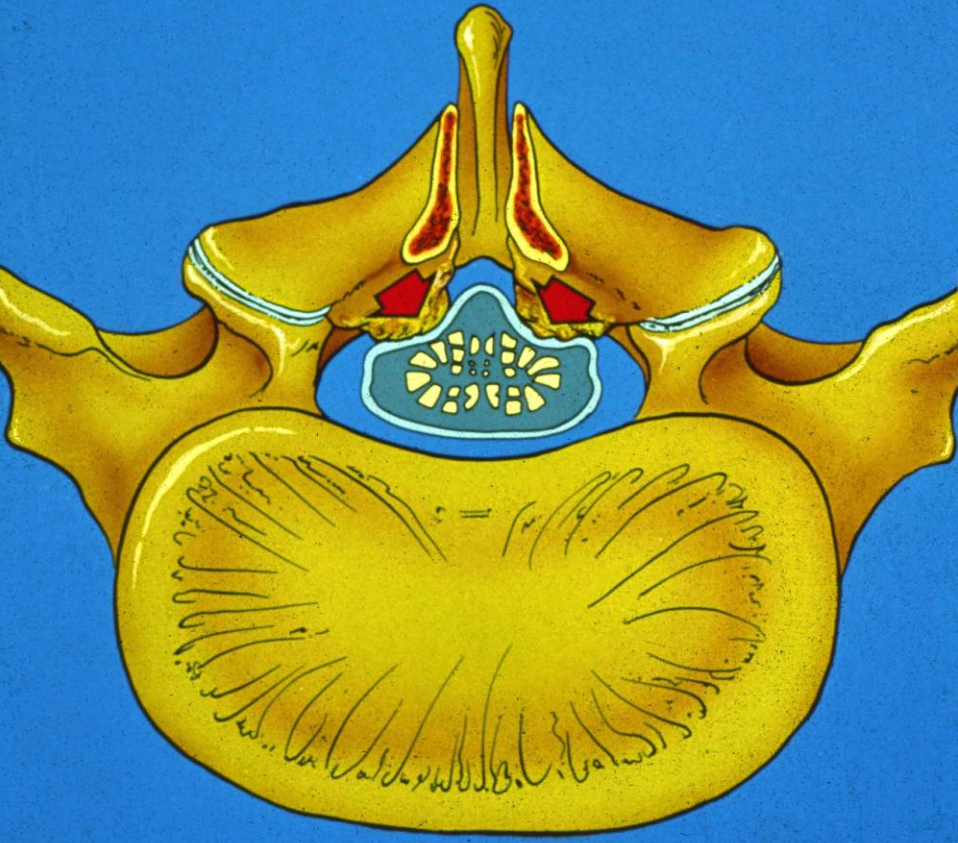
C



# SPINAL STENOSIS

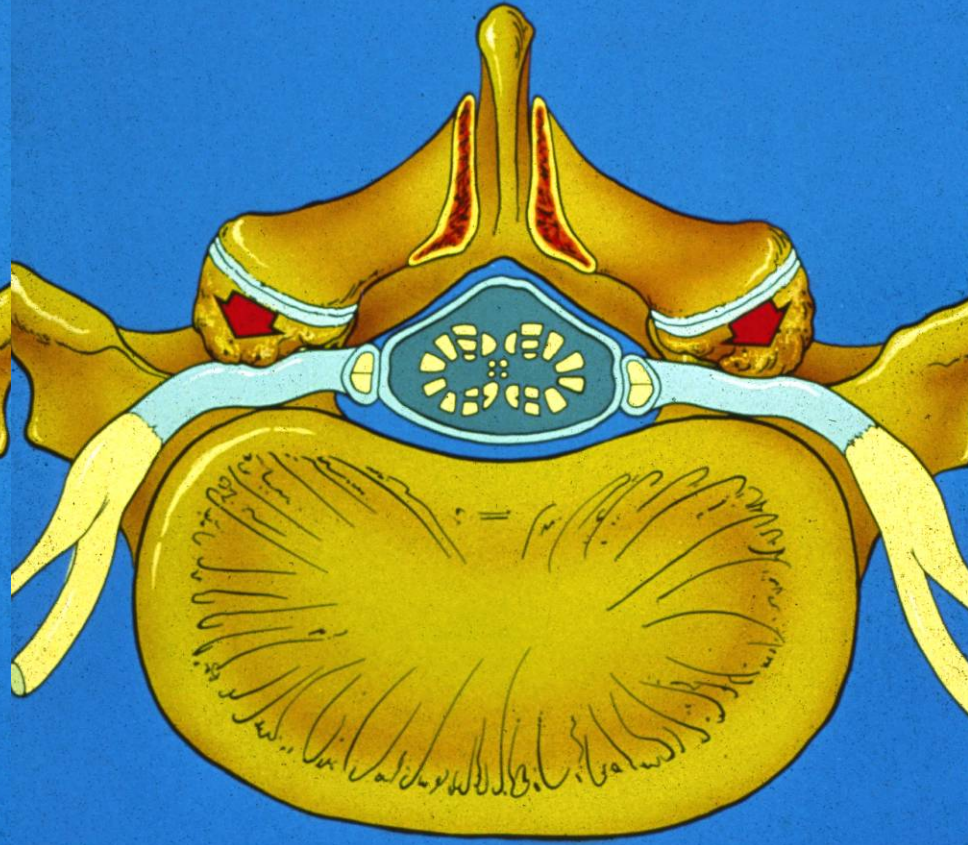
# CENTRAL STENOSIS

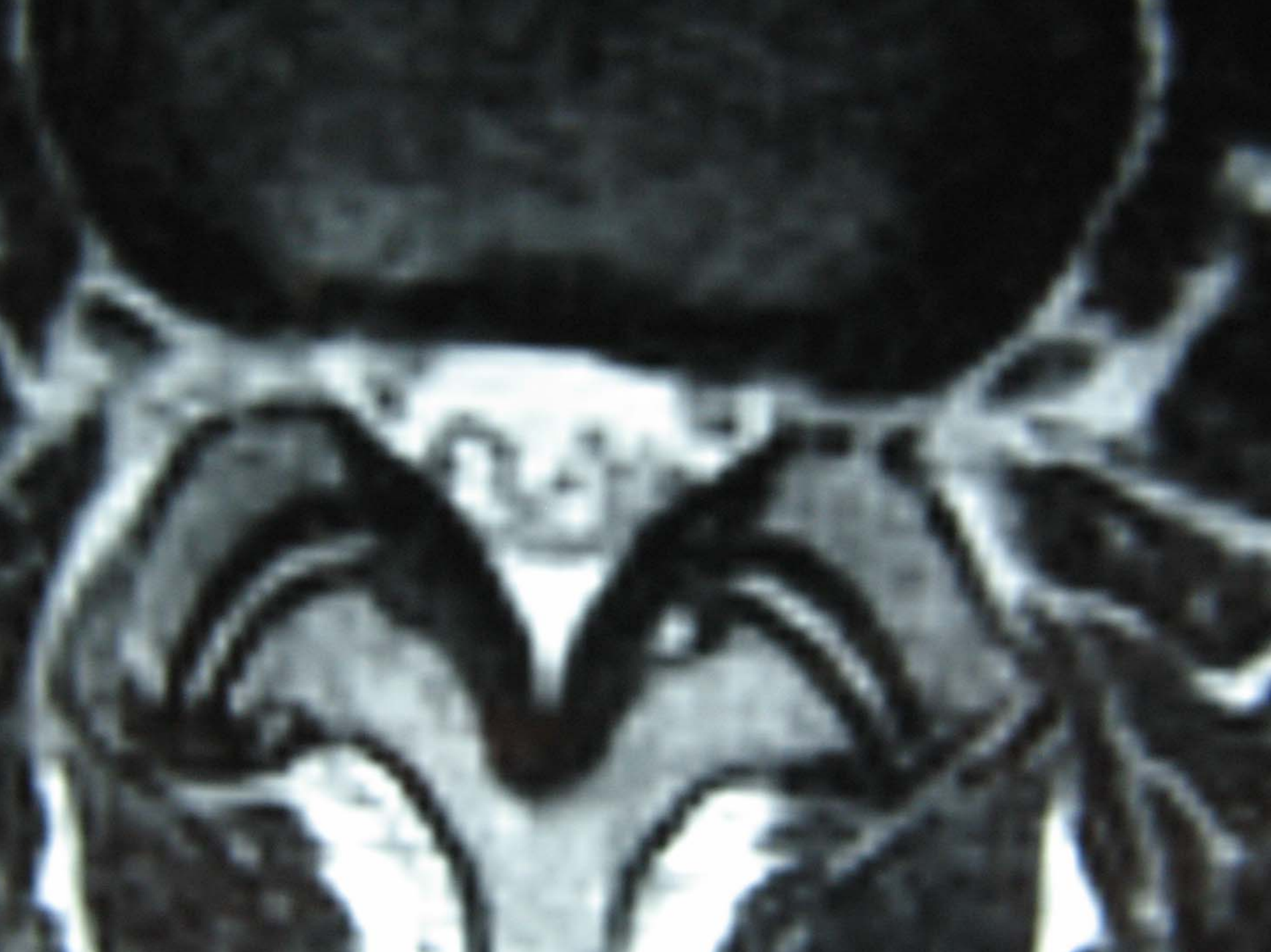
Superior View

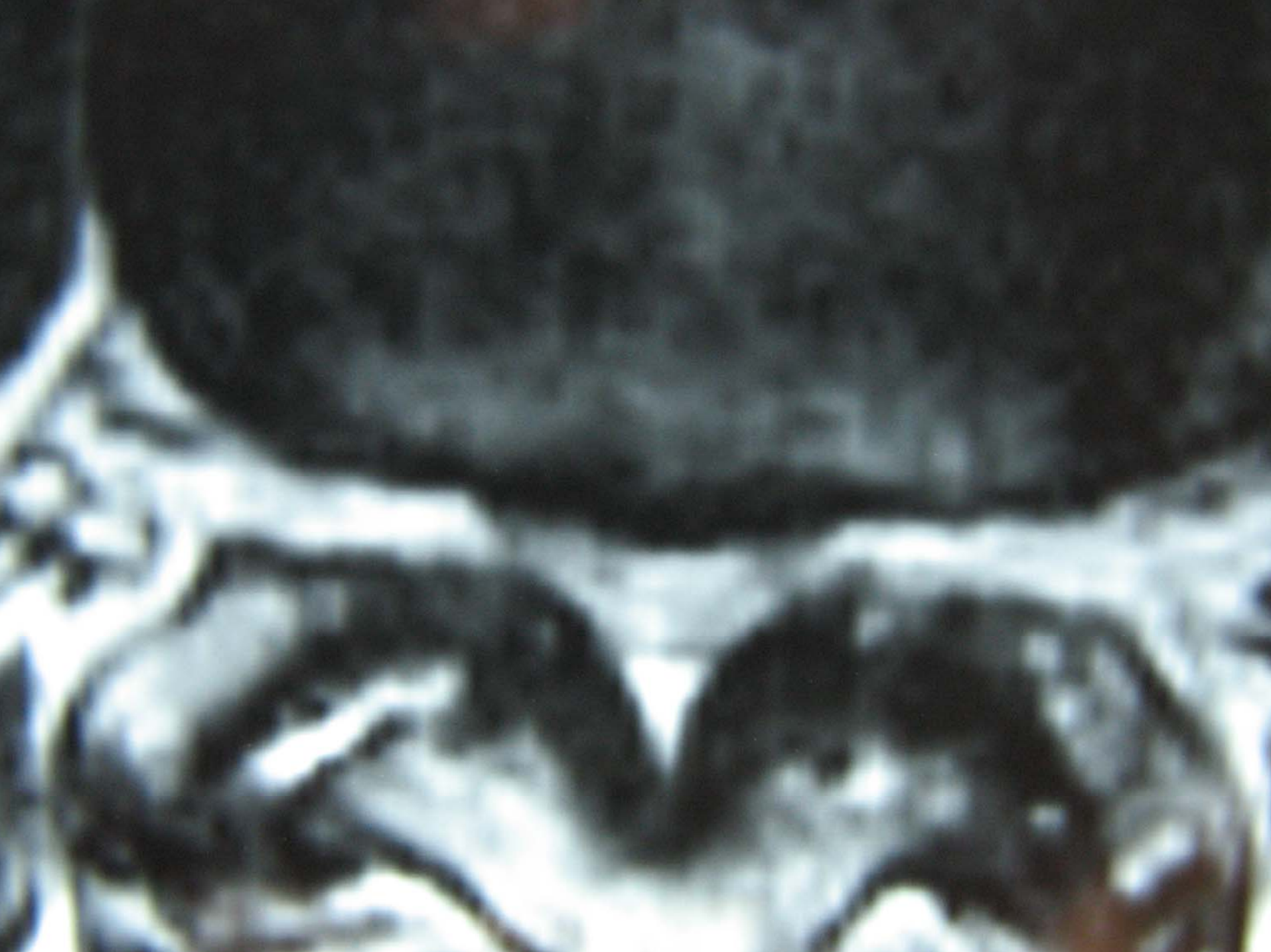


# LATERAL STENOSIS

Superior View



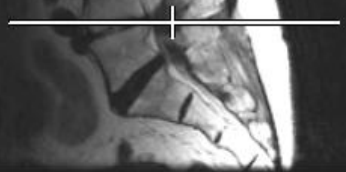




Se  
Lo  
39

A  
HFS

MRI of SLO  
BLOCK, ERNEST J.  
540107  
3/07/08 12:19:36

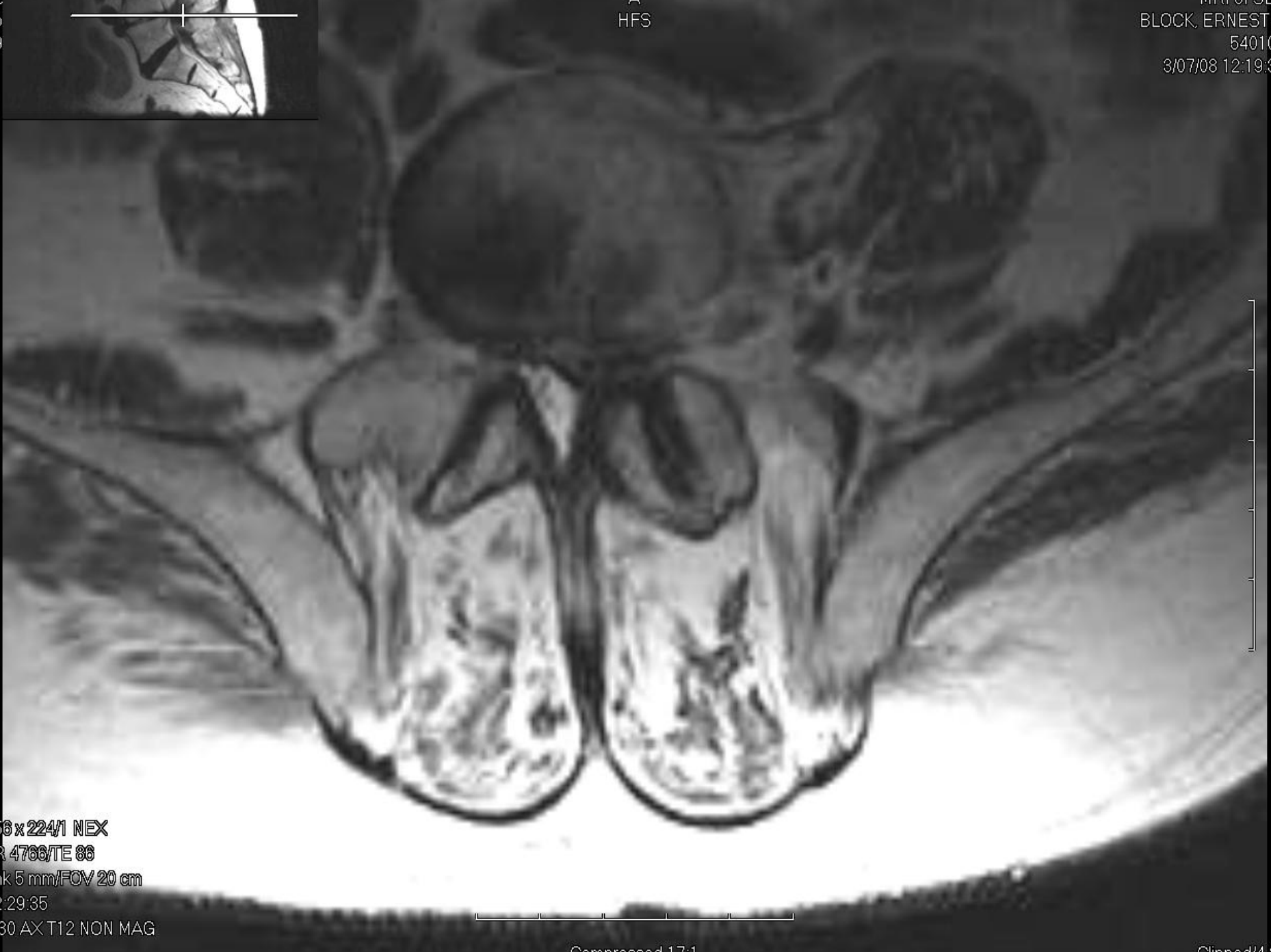

R

256 x 224/1 NEX  
TR 4766/TE 86  
Thk 5 mm/FOV 20 cm  
12:29:35  
7/30 AX T12 NON MAG

Compressed 17:1

Clipped/4.8x

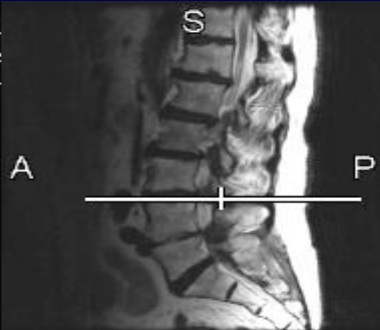



Ser: 5  
Loc: 4  
393 /

A  
HFS

MRI of SLO  
BLOCK, ERNEST J.  
540107  
3/07/08 12:19:36



R

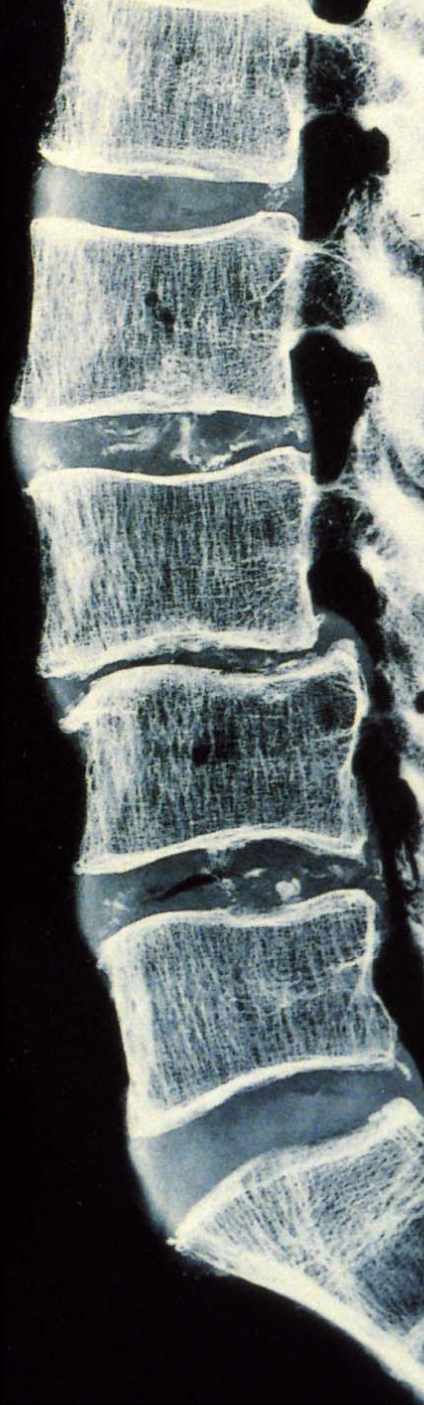
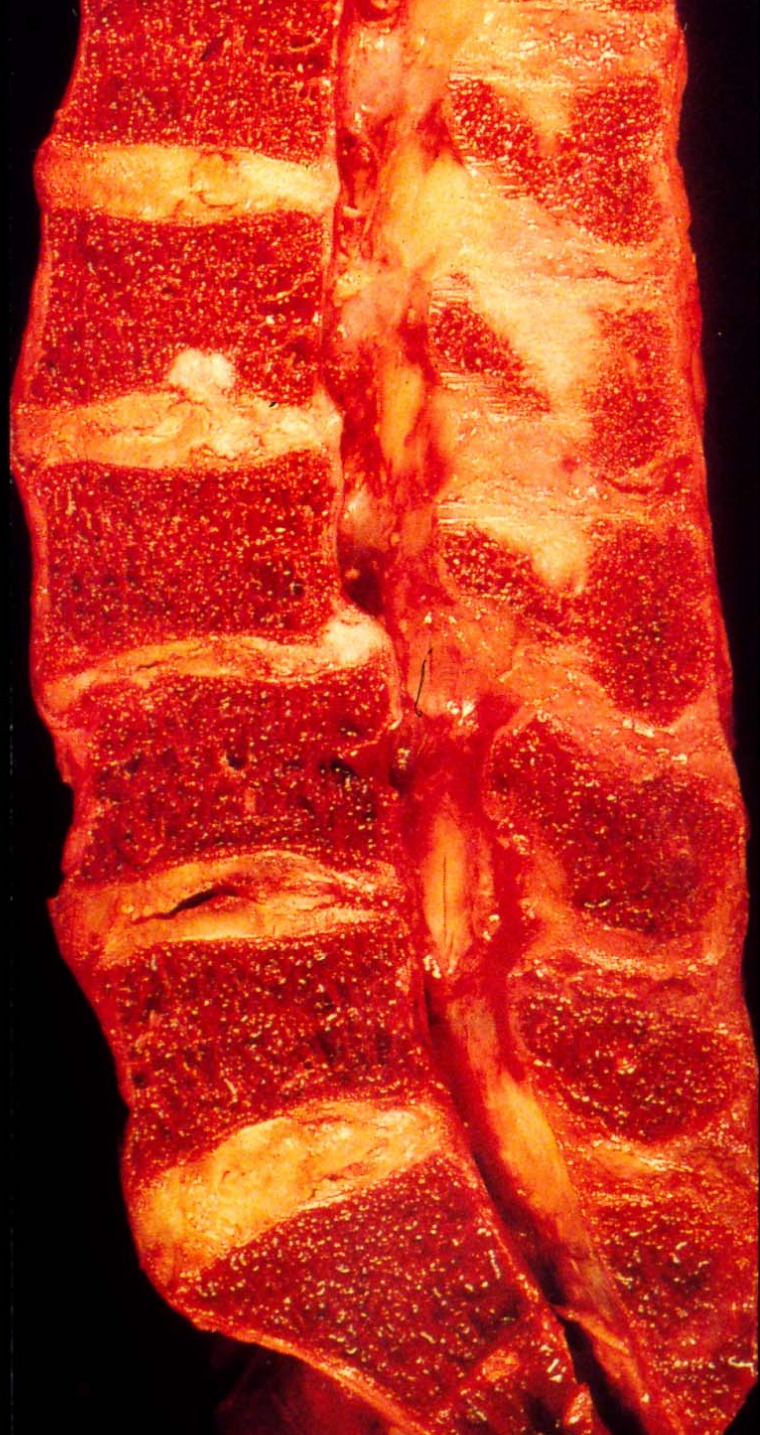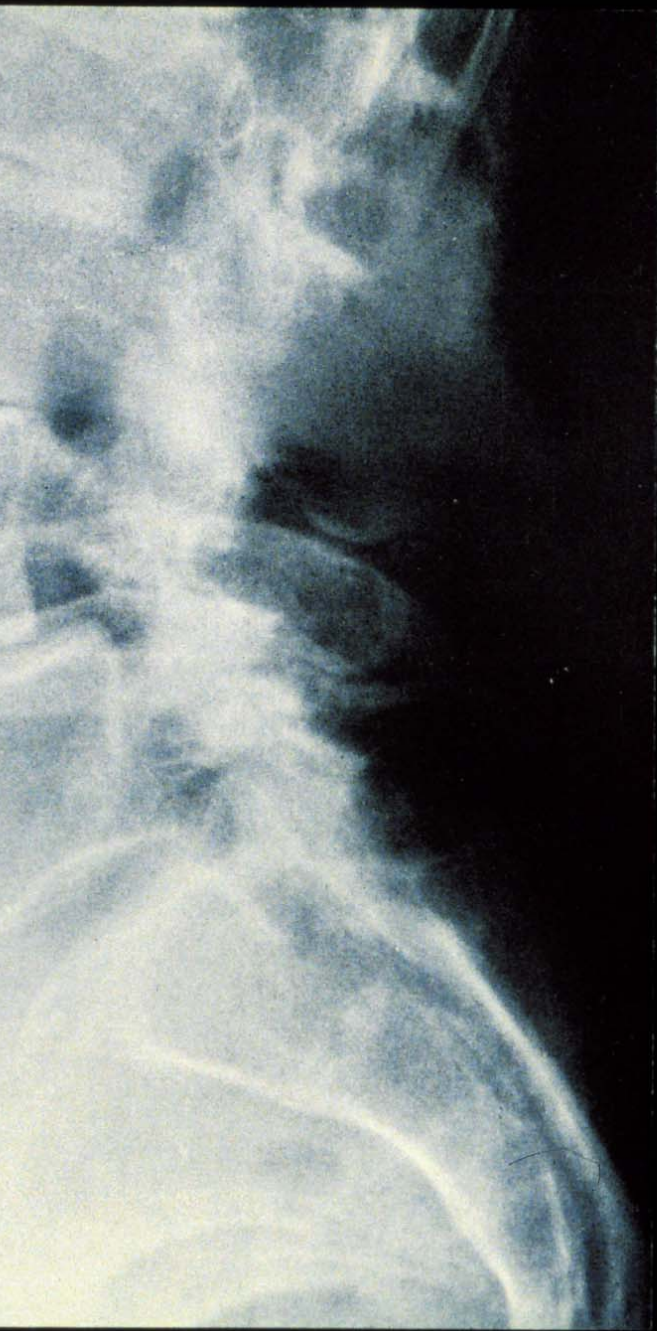L

256 x 224/1 NEX  
TR 4766/TE 86  
Thk 5 mm/FOV 20 cm  
12:29:35  
12/30 AX T12 NON MAG

Compressed 17:1

3.0x

# DEGENERATIVE SPONDYLOLISTHESIS



Ser: 2/Img: 6  
Loc: 5.0 mm  
547 /2098

S  
HFS

MRI of San Luis Obispo.  
KELLY, CANDACE  
481916  
6/12/06 11:05:10

A

P

320 x 224/2 NEX  
TR 2600/TE 109/Flip Angle 90  
Thk 4 mm/FOV 28 cm  
11:07:11  
6/10 S T2 TR=2600 TE=109.44



Compressed 9:1

Clipped/3.1x

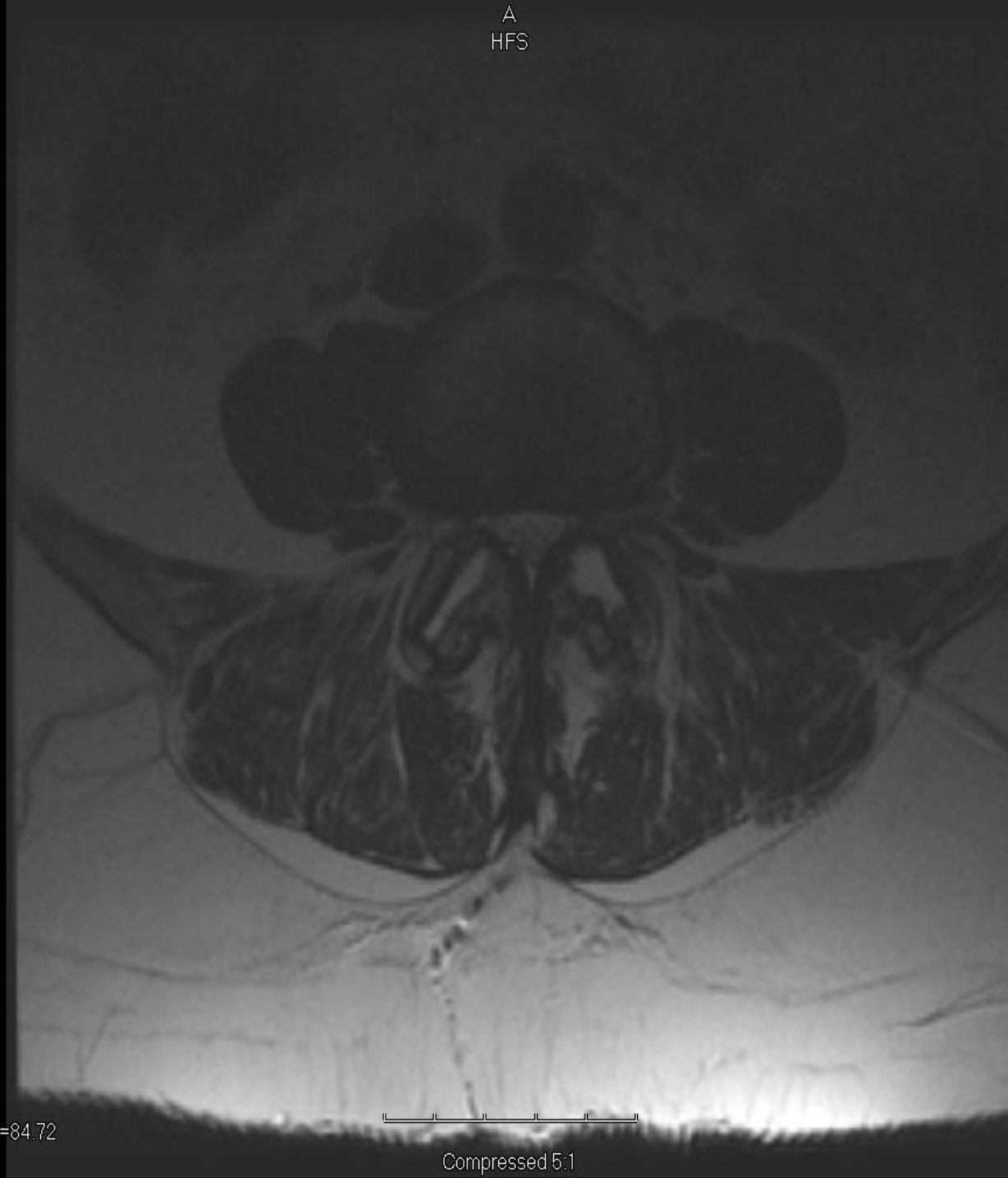
Ser: 6/lmg: 23  
Loc: -57.7 mm  
1050 /3105

A  
HFS

MRI of San Luis Obispo.  
KELLY, CANDACE  
481916  
6/12/06 11:05:10

R

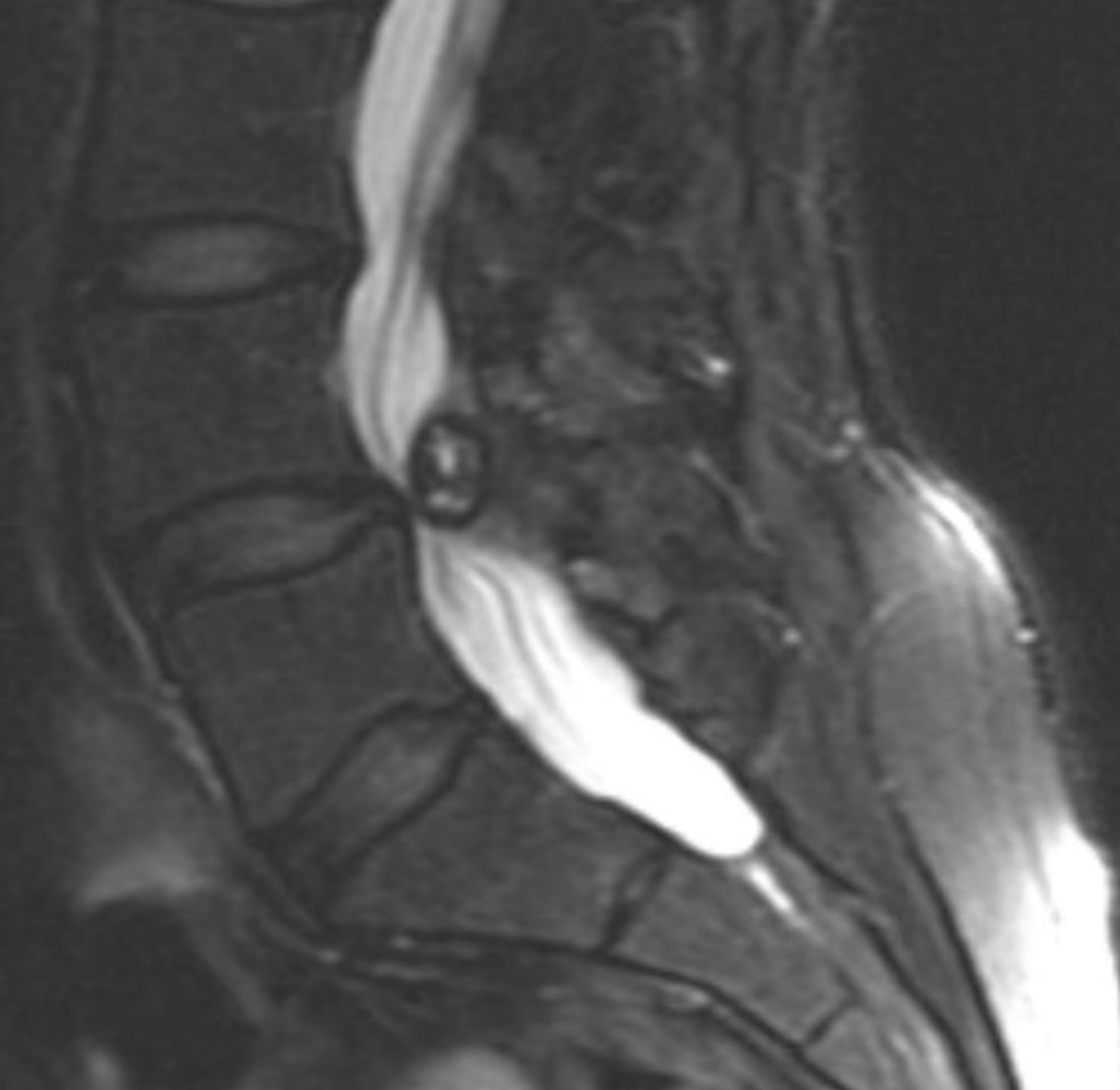L



256 x 224/1 NEX  
TR: 4816/TE 84  
Thk 4 mm/FOV 20 cm  
11:17:22  
23/32 A T2 TR=4816.66 TE=84.72

Compressed 5:1

3.4x



A

P

